

Using Olivamine® in a Skin Cream* to Improve Xerosis and Skin Quality


Dawn R. Fortna RN, MEd, CDE, CWOCN
Ephrata Community Hospital
Ephrata, Pa

Elizabeth O'Connell-Gifford, MBA, BSN, RN, CWOCN, DAPWCA
Medline Industries, Inc.
Berne, NY

Study # LIT671

This study was sponsored by:

Educare[™]
wound & skin care education

The clinical education division of  **MEDLINE**

©2008 Medline Industries, Inc. One Medline Place, Mundelein, IL 60060
Medline and Educare are registered trademarks of Medline Industries, Inc.
1-800-MEDLINE (1-800-633-5463) www.medline.com

MKT208135/LIT671/2.5M/K&M7

Presented at the Symposium on Advanced Wound Care, San Diego, CA, April 2008 and
World Union of Wound Healing Societies, Toronto, Canada, June 2008.

Using Olivamine® in a Skin Cream* to Improve Xerosis and Skin Quality

PROBLEM

Our aging and diabetic population presents with skin issues often resulting in skin injury and increased costs. Both aging and autonomic neuropathy causes a decrease in the sweat and oil production resulting in xerosis. Our goal was to decrease these issues and costs of secondary injuries, and improve quality of life for our patients.

METHODOLOGY

70 patients were selected to participate in a skin care product trial. Criteria for inclusion was high risk for skin breakdown, characteristics of xerosis defined as abnormally dry skin with fine lines, scaling, and fissures, and/or a diagnosis of diabetes with skin concerns/neuropathic pain. Untreated xerosis may lead to itching and scratching, pain, and cellulitis. Excluded were confused or non-verbal patients. Skin repair cream containing Olivamine was applied daily to the patients' legs, and feet, after cleansing, for a period of 4 weeks. Skin was evaluated weekly for integrity. Pain was documented using a 0-10 pain scale. Patients were queried regarding itchiness.

RATIONALE

Olivamine delivers amino acids, antioxidants (hydroxytyrosol), vitamins, and Methylsulfonylmethane to the skin. Transepidermal water loss is preserved with a dimethicone base, preventing damage from dehydration and decreasing pruritis.

OUTCOME

All participants in the study exhibited improvement of the xerosis, fine lines, and scaling of the skin. Patients reported a decrease in itching and pain upon application of the product and stated how good their skin felt. Upon assessment, the skin integrity appeared much improved.

CASE STUDY 1

AW

This 71 year old female has type 2 diabetes. She presented to our clinic for a sacral wound but was identified as having concerns with xerosis, fine lines, and pain in her legs as well (Figure 1a and 1b). She describes the pain level as 3 on the scale of 0-10. Since daily application of the Olivamine containing product, she has had no xerosis or fine lines, her pain has subsided, and her skin appears much healthier (Figure 1c right leg, and 1d left leg).

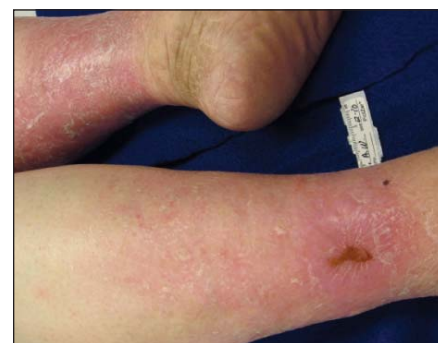

Figure 1a

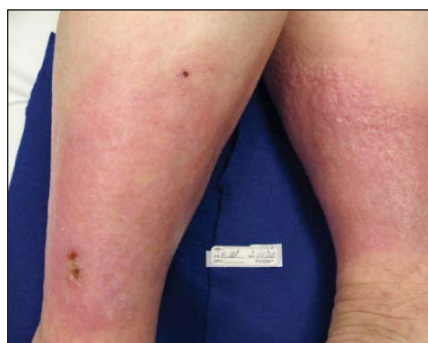

Figure 1b – 2 weeks

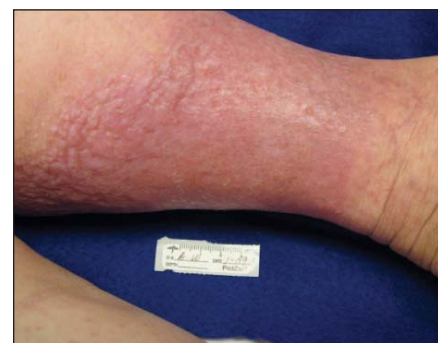

Figure 1c – left leg, 5 weeks

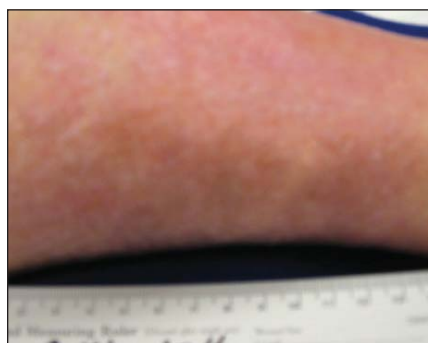

Figure 1d – right leg, 4 weeks

CASE STUDY 2

GM

This 86 year old male has a history of type 2 diabetes and requires renal dialysis. He presents with chronic xerosis of his lower legs causing fine lines, fissures and problems with small open wounds in the area of his one ankle (Figure 2a) Daily application of the Olivamine containing product has decreased his xerosis, fine lines, and scaling and has assisted with healing of his open wounds.

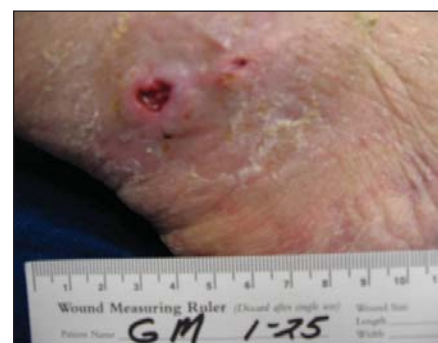

Figure 2a

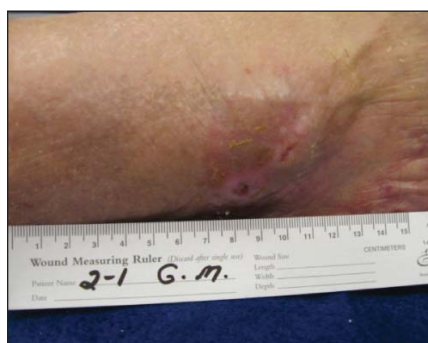

Figure 2b

CASE STUDY 3

RD

This 86 year old male has type 2 diabetes and presented with a diabetic foot wound. He presented for hyperbaric oxygen treatments and was identified as having concerns with xerosis, fine lines, and “itching” of his lower legs. He has areas open and scabbed due to scratching by the patient (Figures 3a and 3b). Since daily application of the Olivamine containing product, he has noticed marked decrease in “itching”. Daily moisturizing and protecting the skin with the Olivamine containing product has greatly improved the general condition of his skin (Figures 3c and 3d).

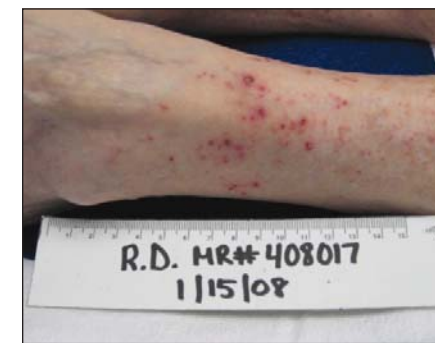

Figure 3a

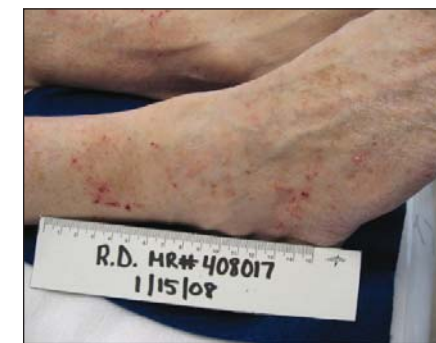

Figure 3b

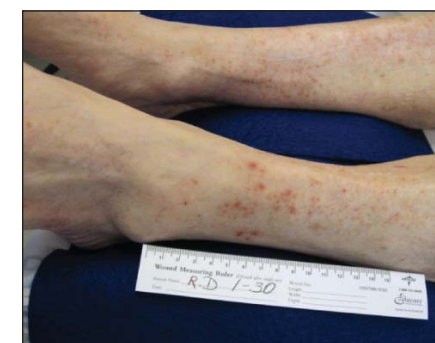

Figure 3c

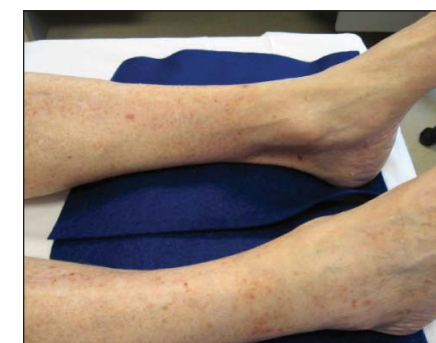

Figure 3d

Assessed Criteria	Patients meeting Criteria	Improved after 4 weeks
XEROSIS	67	67 (100%)
FINE LINES	70	70 (100%)
SCALING OF SKIN	60	50 (100%)
ITCHING	31	31 (100%)
PAIN	10	10 (100%)

CONCLUSION

All participants in the study exhibited improvement of the initial xerosis, fine lines, and scaling of their skin. Those who identified initial itching of the skin, experienced decreased itching following daily application of the Olivamine product. The participants stated that they noticed immediate improvement of their skin and stated that the cream was soothing. Upon assessment, the skin integrity appeared to be much improved and no patient in the study had further skin breakdown while using the product. Those participants experiencing pain and burning prior to the Olivamine preparation, experienced pain reduction of at least 3-4 points on the 0-10 scale following application of the Olivamine product.

These results demonstrate that a program of cleansing, moisturizing, and protecting the skin with the Olivamine containing product improved skin outcomes including skin integrity, prevention of breakdown of fragile skin, and decreased pain and itching for the participants. The quality of life issues are evident by the number of participants that inquired about purchasing the product for continued use following the completion of the study due to their satisfaction of the product's results.

REFERENCES

1. Fore J. “A Review of skin and the effects of Aging on Skin Structure and Function.” *Ostomy/Wound Management*, September 2006: 24-32.
2. Scarborough-Roessler P. “Keeping the Foot Attached to the Leg.” Presentation January, 2003. Educators 2000 Plus.
3. Van Gills, C. and Stark, L. “Diabetes Mellitus and the Elderly: Special Considerations for Foot Ulcer Prevention and Care.” *Ostomy Wound Management*, 2006:52(9)50-56.
3. Remedy. www.medline.com/Woundcare/products/remedy Retrieved 2/17/2007.

*Remedy Skin Repair Cream from Medline Industries, Inc., Mundelein, IL